



Owner's Copy

PennHIP Report

Referring Veterinarian: Dr Diego Florez
 Email: Debbie@aztecanimalhospital.net

Clinic Name: Aztec Animal Hospital
 Clinic Address: 8140 E McDowell Rd.
 Scottsdale, AZ 85257
 Phone: (480) 945-8671
 Fax: (480) 990-1172

Patient Information

Client:
 SAMANTHA DARLING

Tattoo Num:

Patient Name: DUCHESS

Patient ID: 17072

Reg. Name: POWER PAWS UMA ROYAL GOLD
 DUCHESS CGC TKI

Registration Num: SR92768703

PennHIP Num: 119608

Microchip Num: 837620349

Species: Canine

Breed: GOLDEN RETRIEVER

Date of Birth: 31 Mar 2016

Age: 27 months

Sex: Female

Weight: 60 lbs/27.2 kgs

Date of Study: 20 Jun 2018

Date Submitted: 21 Jun 2018

Date of Report: 22 Jun 2018

Findings

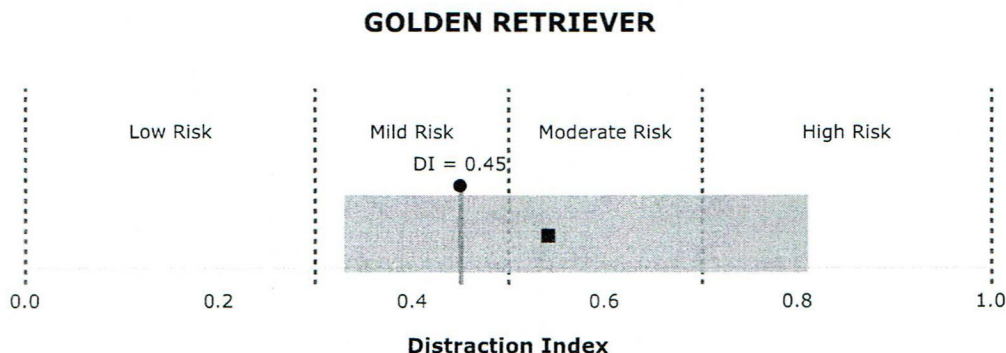
Distraction Index (DI): Right DI = 0.45, Left DI = 0.40.
 Osteoarthritis (OA): **No radiographic evidence of OA for either hip.**
 Cavitation/Other Findings: No cavitation present.

Interpretation

Distraction Index (DI): The laxity ranking is based on the hip with the greater laxity (larger DI). In this case the DI used is 0.45.

OA Risk Category: The DI is between 0.31 and 0.49. This patient is at mild risk for hip OA.

Distraction Index Chart:



Breed Statistics: This interpretation is based on a cross-section of 19004 canine patients of the GOLDEN RETRIEVER breed in the AIS PennHIP database. The gray strip represents the central 90% range of DIs (0.33 - 0.81) for the breed. The breed average DI is 0.54 (solid square). The patient DI is the solid circle (0.45).

Summary: The degree of laxity (DI = 0.45) falls within the central 90% range of DIs for the breed. This amount of hip laxity places the hip at a mild risk to develop hip OA. **No radiographic evidence of OA for either hip.**